

Successful Treatment of Crush Syndrome Complicated with Multiple Organ Dysfunction Syndrome Using Hybrid Continuous Renal Replacement Therapy

Qin Wei Su Baihai Fu Ping Chen Xiaolei Li Jing Zhen Rong

Department of Medicine, Division of Nephrology, West China Hospital, Sichuan University, Chengdu, China

Key Words

Crush syndrome · Multiple organ dysfunction syndrome · Hybrid continuous renal replacement therapy

Abstract

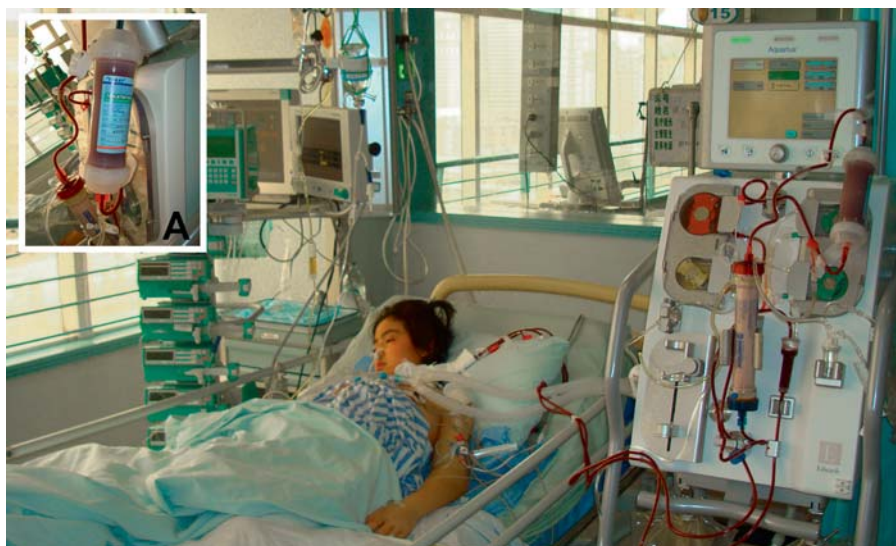Background: The M8.1 'Wenchuan' earthquake occurred on May 12th 2008 causing many injuries and casualties. We report a case with crush syndrome and multiple organ dysfunction syndrome (MODS) successfully treated with hybrid continuous renal replacement therapy (CRRT). **Method:** The patient is a 16-year-old female who was rescued from a collapsed building after 17 h. Emergency amputation was performed. Infections and crush syndrome caused sepsis, acute respiratory distress syndrome, acute renal failure, heart failure, liver dysfunction and disseminated intravascular coagulation in a short time. Hybrid CRRT including high volume hemofiltration, low temperature blood purification, hemoperfusion using endotoxin adsorbent as well as plasmapheresis was performed. **Result:** After the hybrid CRRT treatment, the patient's condition improved progressively. Functions of lung, heart, liver and kidney recovered. Sepsis was controlled. CRRT treatment continued for 550 h without stop. She was followed up for 6 months without any sign of residual organ dysfunction. **Conclusion:** Hybrid CRRT is an effective treatment for patients with severe crush syndrome complicated with MODS.

Copyright © 2009 S. Karger AG, Basel

On May 12th 2008 at 14:28 local time, an earthquake, with a magnitude of 8.1 on the Richter scale, occurred in the densely populated region of Wenchuan in southwest China. It caused heavy casualties and injuries. Many patients with crush syndrome were hospitalized after the earthquake. Severe crush syndrome led to hyperkalemia, acute renal failure (ARF), infection, sepsis, disseminated intravascular coagulation (DIC) and even multiple organ dysfunction syndrome (MODS), which has a considerably high mortality [1]. Hybrid continuous renal replacement therapy (CRRT) clears variety metabolic products and toxins through different blood purification modes, which is very effective in the treatment of critically ill patients. Here, we report the case of a patient with crush syndrome and MODS treated successfully with hybrid CRRT.

Case Report

The patient is a 16-year-old girl. After the earthquake, she was buried under a collapsed building for about 17 h before being rescued. Because of severe crush injuries of the left leg, an emergency amputation was performed in a tent hospital on May 13th. Dyspnea, oliguria (urine output 100–300 ml/day) and fever ($T > 39^{\circ}\text{C}$) developed after the operation. Three sessions (once daily for 3 days, 2–4 h each time) of intermittent hemodialysis (IHD) were performed because of ARF complicated with hyperkalemia in the



Color version available online

Fig. 1. The patient was undergoing hybrid CRRT. **A** The PMX-20 cartridge was connected to the CRRT blood circuit during treatment.

local hospital. On May 15th, her status deteriorated; tracheal intubation and mechanical ventilation were applied because of acute respiratory distress syndrome (ARDS), then she was transferred to the ICU ward of West China Hospital late in the night of May 15th.

Physical examination at admission indicated: T 40.5°C, HR 185 bpm, BP 184/115 mm Hg, conscious was unclear. Respiratory rate was 35 times/min, but PaO₂ (56 mm Hg) and SaO₂ (85%) was decreased under FiO₂ 100% oxygen therapy. Diffused rales and crackles were heard in bilateral lungs. The left leg was amputated from the upper 1/2 of the thigh and severe swelling was observed in the residual part of the leg. Purulent secretion was seen at the amputation site. Many contusion wounds and swellings were noticed in the right leg (with increased tension). Laboratory tests indicated: serum creatinine (sCr) 327 μmol/l, BUN 20.4 mmol/l, TB (total bilirubin) 157 μmol/l, DB (direct bilirubin) 134 μmol/l, ALT (alanine transaminase) 225 IU/l, AST (aspartate aminotransferase) 561 IU/l, CK (creatin kinase) 6,311 IU/l, RBC 2.25 × 10¹²/l, Hgb 67g/l, Hct 0.19, WBC 55.41 × 10⁹/l, K 6.8 mmol/l, serum myoglobin >4,000 ng/ml, PT (prothrombin time) 19.9 s, APTT (activated partial thromboplastin time) 102.6 s, TT (thrombin time) 42.4 s. Chest X-ray indicated a large area of effusion lesions. APACHE II and MODS scores at admission were 41 and 19, respectively. The patient was diagnosed as ‘crush syndrome, rhabdomyolysis, MODS: ARDS, ARF, DIC, acute left heart failure, anticoagulation disorder, impaired liver function, infection of amputation site, sepsis’.

Continuous veno-venous hemofiltration (CVVH) was carried out because of ARF and MODS complicated with an unstable hemodynamic status. CVVH was performed using the Baxter Acuraquis system. A Baxter Renaflo HF1200 (1.25 m², molecular weight cutoff 65 kDa) hemofilter was used (in order to ensure the efficiency of membranes, the hemofilter was replaced every 24 h, or if the filter clotted prematurely). Blood flow was set at 180–200 ml/min. Regional citrate anticoagulation was chosen. Dose of replacement fluid was 40 ml/kg/h, with 70% predilution and 30%

postdilution. Net fluid removal was set according to the central venous pressure (CVP) level. sCr, BUN and K decreased to 115 μmol/l, 8.69 mmol/l and 3.4 mmol/l, respectively, after 48 h CVVH. However, infection deteriorated despite the use of antibiotics (meropenem + vancomycin). Blood, wound secretions and sputum culture indicated multiple pathogenic microorganisms including *Klebsiella pneumoniae* (extended-spectrum β-lactamases, ESBL), *Acinetobacter baumannii* and *Candida tropicalis*. Considering that the patient’s status deteriorated (body temperature persistently >40°C), we changed the antibiotics to imipenem and cilastatin + caspofungin. In order to control the patient’s severe sepsis status, hybrid CRRT (CVVH + hemoperfusion + plasmapheresis) was carried out on May 17th 2008. CVVH mode was changed to low temperature (32°C), high-volume hemofiltration (HVHF, replacement fluid dosage 60 ml/kg/h). Hemoperfusion (4 h daily) was carried out using endotoxin adsorption cartridge (Toraymyxin PMX-20, Japan), which was assembled in the blood flow circuit right after the hemofilter (fig. 1). During the hemoperfusion, the blood flow rate was reduced to 100 ml/min, and HVHF mode was changed to SCUF (slow continuous ultrafiltration) mode. After the hemoperfusion, plasmapheresis (3 h daily, replaced by 1,000 ml fresh-frozen plasma every hour) was carried out using Microplas MPS05.

The patient’s general status was stabilized after the above-mentioned treatment. Three days later, vital signs were T 38.4°C, HR 110 bpm, RR 18 times/min, BP 140/70 mm Hg. WBC count decreased to 21.1 × 10⁹/l. Liver and coagulation dysfunction recovered (fig. 2). X-ray chest film indicated remarkable relieve of pulmonary lesions. APACHE II and MODS scores decreased to 12 and 8, respectively. Thereafter, the blood purification mode was changed back to normal dosage CVVH (35 ml/kg/h). The patient’s status improved progressively. Mechanical ventilation was stopped 12 days later, and CVVH was stopped after a continuous treatment of 550 h. APACHE II and MODS scores dropped to 2 and 0, respectively, at that time. She was followed up for 6 months till now without signs of further organ dysfunction.

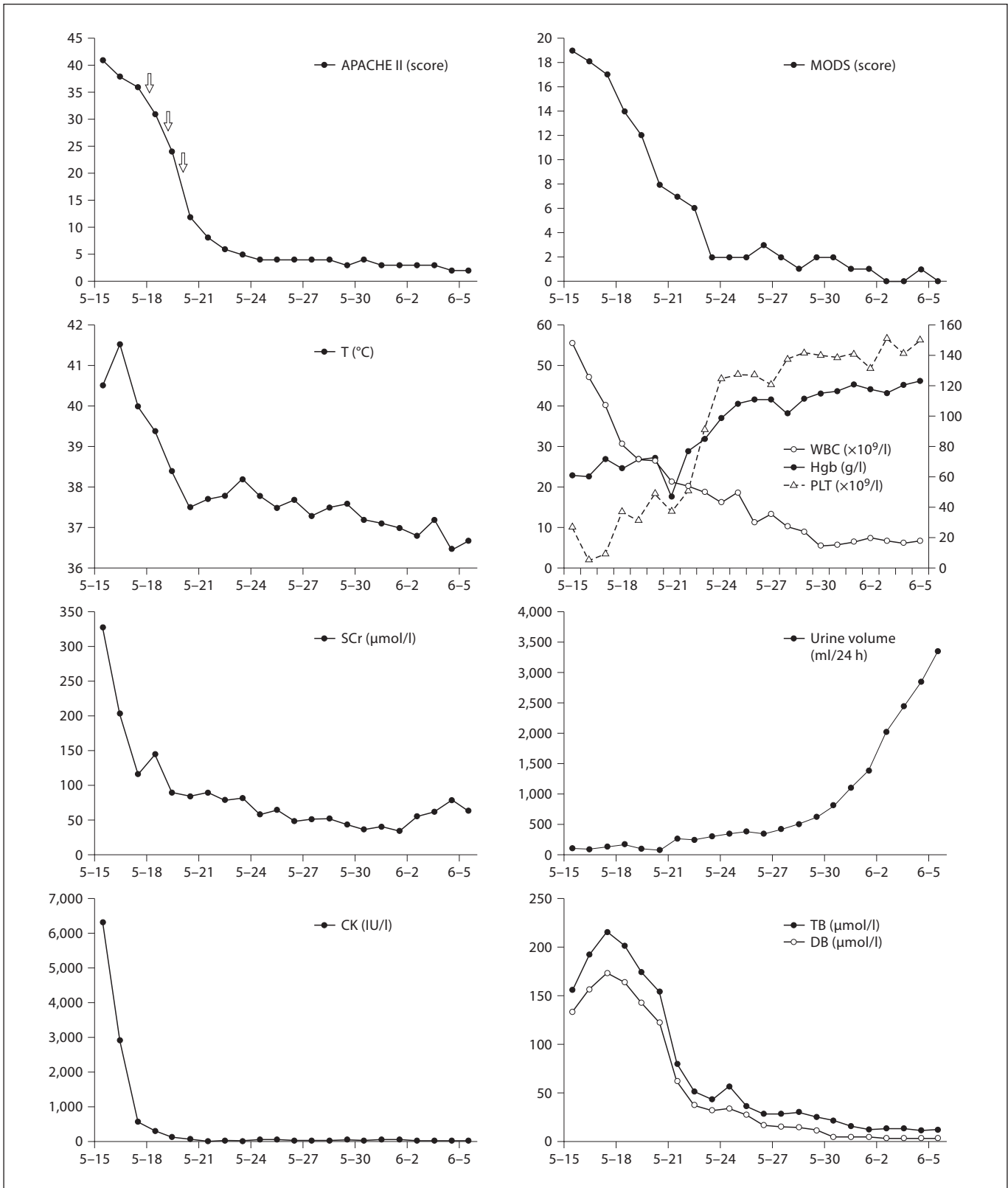


Fig. 2. Changes of main laboratory indexes and critically ill scores of the patient. Arrows indicate sessions of hemoperfusion and plasmapheresis. Normal range: TB 5–28 $\mu\text{mol/l}$, DB $<8.8 \mu\text{mol/l}$, ALT $<38 \text{ IU/l}$, AST $<37 \text{ IU/l}$, CK 20–140 IU/l.

Discussion

The M8.1 'Wenchuan' earthquake caused great life losses to China. According to official reports, it caused 69,225 deaths and 374,640 wounded; 96,463 were admitted to hospitals because of earthquake-related injuries. Among the hospitalized cases, crush injury was one of the most common medical problems. Crushing injury may lead to serious medical condition characterized as hyperkalemia, myoglobinuria, ARF and even multiple organs dysfunction [1]. It was reported that crush syndrome was the second cause of death of earthquake injury patients. Therefore, treatment of crush syndrome is crucial to the prognosis of these patients.

ARF is the most common complication of crush syndrome. In the Marmara (Turkey, 1999) earthquake, 12% hospitalized patients were diagnosed as crush syndrome and 8.9% patients needed renal replacement therapy [2, 3]. After the Wenchuan earthquake, 2,717 patients were transferred to West China Hospital, among them, 146 (7.91%) were diagnosed as crush syndrome. Acute kidney injury induced by crush syndrome was noticed in 62 patients. IHD, peritoneal dialysis (PD) and CRRT were needed in 45 patients.

Comparing with IHD and PD, CRRT has advantages in treating crush syndrome patients. (1) It can remove myoglobin (Myo), whereas IHD can not because of large molecular weight (17 kDa) of Myo [4–6]. (2) It can be applied in patients with unstable hemodynamic status such as hypotension or severe tachycardia [7]. (3) Volume control of CRRT is more accurate than IHD and PD. (4) CRRT guarantees a stable homeostasis which could not be achieved by IHD. (5) CRRT can remove cytokines and inflammatory media, which were abundant in patients with sepsis and were related to poor prognosis [8]. CVVH could remarkably remove these media [9] and improve the prognosis, both in the survival of kidney function and the decrease of mortality [10–13]. (6) Special blood purification modes, such as hemoperfusion and plasmapheresis, are effective in treating patients with sepsis and MODS [14]. Therefore, in earthquake-injured patients with sepsis or MODS, application of multiple-mode hybrid CRRT treatment is sometimes important to improve prognosis.

In the current case, severe crush syndrome caused ARF. Severe infections led to sepsis rapidly, which manifested as hyperpyrexia, hyperkalemia, increasing of serum BUN and Cr. Although several sessions of IHD were performed, the hyperkalemia and azotemia were not controlled. Considering the poor hemodynamic status of the

patient and advantages of HVHF in treating critically ill patients [12], especially those complicated with progressing hyperkalemia and azotemia, low temperature (32°C) HVHF (60 ml/kg/h) was performed. After the treatment, hypercatabolic state and hyperpyrexia were controlled, hyperkalemia was reversed and sCr as well as BUN levels were decreased. Meanwhile, serum Myo and CK decreased progressively to normal levels, which also provide a favorable basis for the recovery of the patient (fig. 2).

In the chaotic situation in earthquake rescue works, infections were sometimes inevitable. Just as in this patient, the emergency tent operation without perfect disinfection led to serious infections causing life-threatening sepsis. Although multiple antibiotics were used, the patient's general status deteriorated rapidly. Endotoxin, which may cause systemic inflammatory response syndrome (SIRS) reactions, is considered one of the principal biological substances causing Gram-negative septic shock. However, anti-endotoxin drug therapies failed to demonstrate a consistent clinical benefit. In order to clean endotoxin, multiple modes of blood purification combining HVHF, hemoperfusion and plasmapheresis were applied. During HVHF, a hemofilter with a high molecular weight cutoff level (65 kDa) was used, which guaranteed the removal of small-to-medium-sized solutes such as cytokines released by endotoxin-activated inflammatory cells. During the hemoperfusion, a column containing special fiber composite immobilized antibiotic polymyxin B, which has a high affinity for endotoxin, was used. It was reported that it could effectively bind endotoxin *in vitro* and *in vivo* [14, 15]. The rationale underlying extracorporeal therapy with endotoxin adsorbent hemoperfusion would be to remove circulating endotoxin by adsorption, thus preventing progression of the biological cascade of sepsis. During plasmapheresis, the patient's plasma was exchanged by healthy fresh-frozen plasma. This therapy could remove all kinds of cytokines, inflammatory media, and exogenous and endogenous toxins in a nonspecific manner. After the treatment, symptoms of sepsis (fever, leukocytosis, and unstable hemodynamic status) and liver dysfunction (increase of bilirubin and transaminase levels) were all relieved significantly (fig. 2) just as reported by other authors [14, 16]. The patient's vital signs stabilized immediately after 3 times of hemoperfusion and plasmapheresis.

Acute lung injury (ALI) and ARDS were common complications in patients with severe crush syndrome [8, 17]. Treatment of ALI/ARDS was difficult in these

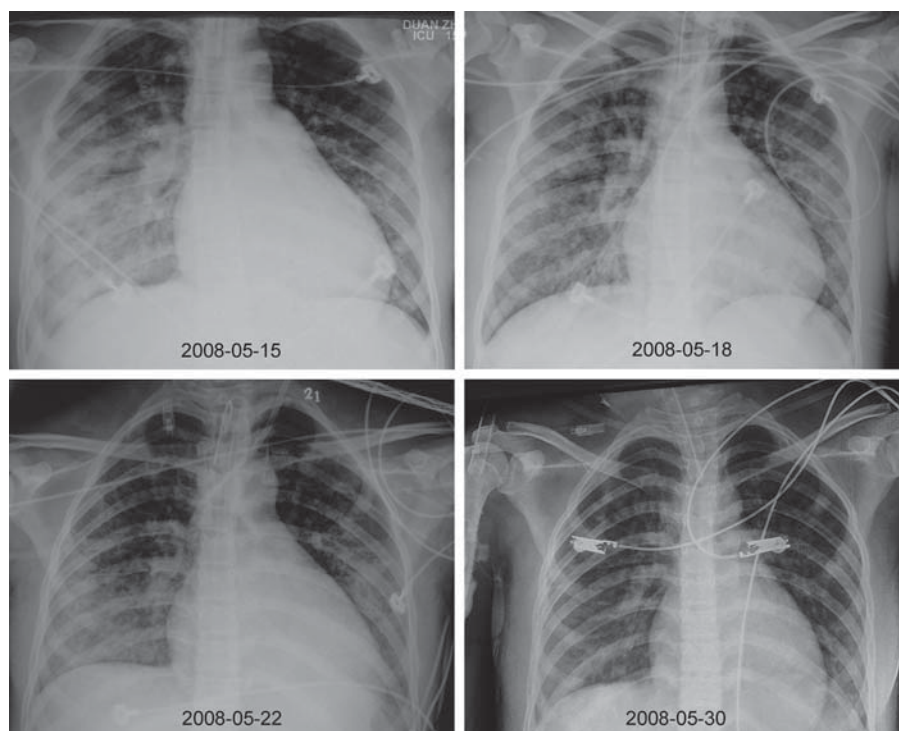


Fig. 3. Changes as seen on chest X-rays of the patient.

patients because most of them were complicated by volume overload and infections which participated in the pathophysiological process of ALI/ARDS. It was reported that CRRT may improve pulmonary gas exchange and arterial oxygenation under ARDS status [18–20] and may be helpful in the treatment of ALI/ARDS. In the current case, sepsis and pulmonary edema induced by crush injury and ARF led to severe ARDS. Although antibiotics, mechanical ventilation and IHD were carried out, ARDS was not controlled in the local hospital. Chest X-ray film indicated severe exudative lesions in bilateral lungs when she was transferred to our ICU. CRRT was applied in order to reverse the volume overload, remove inflammatory media and improve the oxygenation status. After the CRRT treatment, the respiratory indexes improved remarkably. Mechanical ventilation was stopped progressively. Chest X-ray indicated steady and significant improvement of pulmonary exudative lesions (fig. 3).

In this case, crush syndrome was complicated with sepsis and MODS. APACHE II and MODS scores had reached as high as 41 and 19, respectively, which made conventional treatment almost ineffective. However, timely applied multiple-mode hybrid CRRT achieved a more than satisfactory result in this patient. Treatment of

this patient indicated that HVHF, hemoperfusion (endotoxin adsorption) and plasmapheresis were effective in removing toxins, maintaining homeostasis, improving hemodynamic status and supporting organ functions, which is extremely important to the recovery of critically ill patients.

Conclusion

Multiple-mode hybrid CRRT is a promising alternative for earthquake injuries complicated with severe crush syndrome and MODS. Appropriate and timely choice of blood purification modes is of great importance to the prognosis of these patients.

References

- 1 Sever MS, Vanholder R, Lameire N: Management of crush-related injuries after disasters. *N Engl J Med* 2006;354:1052–1063.
- 2 Kantarci G, Vanholder R, Tuğlular S, et al: Acute renal failure due to crush syndrome during Marmara earthquake. *Am J Kidney Dis* 2002;40:682–689.

- 3 Sever MS, Ereke E, Vanholder R, et al: Clinical findings in the renal victims of a catastrophic disaster: the Marmara earthquake. *Nephrol Dial Transplant* 2002;17:1942–1949.
- 4 Shigemoto T, Rinka H, Matsuo Y, et al: Blood purification for crush syndrome. *Ren Fail* 1997;19:711–719.
- 5 Amyot SL, Leblanc M, Thibeault Y, et al: Myoglobin clearance and removal during continuous venovenous hemofiltration. *Intensive Care Med* 1999;25:1169–1172.
- 6 Nicola D, Feng YS, Wu AH, et al: Myoglobin clearance during continuous veno-venous hemofiltration with or without dialysis. *Int J Artif Organs* 1998;21:205–209.
- 7 Baldwin I, Bellomo R, Naka T, et al: A pilot randomized controlled comparison of extended daily dialysis with filtration and continuous veno-venous hemofiltration: fluid removal and hemodynamics. *Int J Artif Organs* 2007;30:1083–1089.
- 8 Ereke E, Sever MS, Serdengecti K, et al: An overview of morbidity and mortality in patients with acute renal failure due to crush syndrome: the Marmara earthquake experience. *Nephrol Dial Transplant* 2002;17:33–40.
- 9 De Vriese AS, Colardyn FA, Philippe JJ, et al: Cytokine removal during continuous hemofiltration in septic patients. *J Am Soc Nephrol* 1999;10:846–853.
- 10 Ronco C: CRRT protects the kidney during acute renal failure. *Int J Artif Organs* 2007;30:279–280.
- 11 Ronco C, Bellomo R: Acute renal failure and multiple organ dysfunction in the ICU: from renal replacement therapy (RRT) to multiple organ support therapy (MOST). *Int J Artif Organs* 2002;25:733–747.
- 12 Cole L, Bellomo R, Journois D, et al: High-volume haemofiltration in human septic shock. *Intensive Care Med* 2001;27:978–986.
- 13 Clark WR, Letteri JJ, Uchino S, et al: Recent clinical advances in the management of critically ill patients with acute renal failure. *Blood Purif* 2006;24:487–498.
- 14 Cruz DN, Perazella MA, Bellomo R, et al: Effectiveness of polymyxin B-immobilized fiber column in sepsis: a systematic review. *Crit Care* 2007;11:R47.
- 15 Cruz DN, Bellomo R, Ronco C: Clinical effects of polymyxin B-immobilized fiber column in septic patients. *Contrib Nephrol*. Basel, Karger, 2007, vol 156, pp 444–451.
- 16 Toft P, Schmidt R, Broechnner AC, et al: Effect of plasmapheresis on the immune system in endotoxin-induced sepsis. *Blood Purif* 2008;26:145–150.
- 17 Nishihara G, Nakamoto M, Yasunaga C, et al: Adult respiratory distress syndrome associated with crush syndrome. *Nephron* 1997;75:488–489.
- 18 DiCarlo JV, Dudley TE, Sherbotie JR, et al: Continuous arteriovenous hemofiltration/dialysis improves pulmonary gas exchange in children with multiple organ system failure. *Crit Care Med* 1990;18:822–826.
- 19 Ullrich R, Roeder G, Lorber C, et al: Continuous venovenous hemofiltration improves arterial oxygenation in endotoxin-induced lung injury in pigs. *Anesthesiology* 2001;95:428–436.
- 20 Schetz M: Non-renal indications for continuous renal replacement therapy. *Kidney Int* 1999;72(suppl):S88–S94.